

The Effectiveness of a 980-nm Diode Laser to Treat Face Haemangioma: A Randomised within-Patient Trial

Noor Taha Ismaeel*

Institute of Laser for Postgraduate Studies, University of Baghdad

Haemangiomas are benign noncancerous vascular malformations of capillaries and are commonly present on the face. All types of lasers are suitable for the management of such vascular lesions. Here, we aimed to determine the effectiveness of a 980-nm diode laser for the treatment of Iraqi patients with facial haemangioma. This randomised trial was conducted at Laser Medicine Research Clinics, Iraq, from 15 October 2018 to 15 August 2019. The improvement of the condition at 6 months was the first endpoint. The patient's quality of life, diminished lesions, and safe administration of diode laser were the second endpoints. At follow-up, the lesions were less elevated, smoother in texture, and the colour had changed from red to pink. Based on these results, this laser is an effective and safe tool for the treatment of haemangiomas of the face.

Keywords: Diode laser; Haemangioma; Randomised within patient; Histogram

I. INTRODUCTION

Haemangiomas are benign vascular proliferation conditions formed by numerous capillary structures that commonly affect the tongue and lips (Husain & Alster, 2016). Haemangiomas in infants are commonly known as strawberry marks. These lesions can occur in any part of the body. Treatment of haemangioma is often unnecessary, but intervention might be needed in some cases (Husain & Alster, 2016; ISSVA, 2018). Lasers are considered an effective treatment for these lesions. The laser light is converted to heat and, on reaching a blood-vessel wall, causes coagulation and vessel occlusion. Although vascular lasers cause non-homogeneous heating within dermal vessels due to their different sizes, the results are effective (Husain & Alster, 2016). There are many methods used to treat haemangiomas, including surgical removal of haemangiomas of the nasal tip (Hamou *et al.*, 2010) and photocoagulation using a diode laser in cases of upper lip haemangioma (Vechio *et al.*, 2013). A CM-neodymium YAG laser has been used to treat vascular lesions caused by haemangiomas (Ulrich *et al.*, 2005), and head and neck haemangioma reduction has been achieved by forced

dehydration with accelerated photocoagulation (FDIP) using a diode laser (Angiero *et al.*, 2008).

On occasion, a haemangioma can detach and cause a slough lesion. The lesions can present with pain, bleeding, scars, or, later on with an infection. However, the most important issue is that this can cause psychological impairment either due to a lack of connection with society or social eating difficulties of patients when they become adults. This trial was conducted to study the efficacy of diode lasers in the treatment of haemangiomas.

II. MATERIALS AND METHODS

A. Study Design and Setting

This study was a randomised within-patient trial (Figure 1), which was carried out at Laser Medicine Research Clinics in Iraq from 15 October 2018 to 15 August 2019. All patients received treatment with a diode laser at 980-nm.

*Corresponding author's e-mail: NoorT1980@outlook.sa

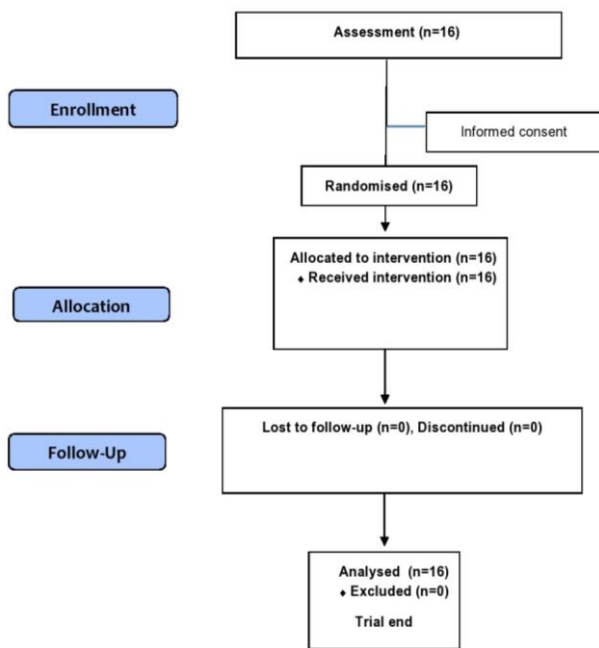


Figure 1. Flow chart of the study. A total of 16 patients were enrolled, and they provided written consent. All patients received the intervention, and all continued to the end of the trial.

B. Participants

Sixteen cases with face haemangiomas. Details of the sites of lesions were documented for all participants.

C. Eligibility Criteria

All patients with face haemangiomas could be included, from dermatological departments.

D. Inclusion Criteria

1. Aged from 5 to 65 years
2. A previous diagnosis of haemangiomas
3. Performance status of patients within 60 – 100 (Karnofsky & Burchenal, 1949)
4. No known allergy to lasers
5. Superficial lesion
6. Willingness to undergo therapy

E. Exclusion Criteria

1. Age less than 5 years or more than 66 years
2. Advanced case
3. Deep lesion
4. Invasive lesion

5. Complicated lesion
6. History of hyper-photosensitivity
7. Pregnant and/or breastfeeding women

F. Interventions

There have been many reports that lasers may have an effect on skin lesions. Here, patients received laser therapy for 12 sessions at two-week intervals. In case of intolerance, the number of sessions could be reduced to 10, 8, 6, or 4. The assessment was performed at each interval to check for undesirable side effects, and this was performed after completing a session. Treatment was stopped if:

1. The patient experienced side effects.
2. The patient experienced a complete disappearance of lesions.
3. The patient wished to withdraw from the process.

G. Outcomes

The first end-point was lesions assessed at 6 months, which included measurement of:

1. The area of haemangioma lesions: the area of lesions was measured using a tape measure (cm).
2. Colour of the lesion: By inspection of the colour of the lesion, such as changes from dark red to bright red or disappearance.
3. Shape of the lesion: Clinical exam by inspection, ugly shape of lesion, may be disappear.

Secondary endpoints were:

1. Improvement of pain from the date of randomisation.
2. Good quality of life and social connections.
3. Growth rate volume assessed (decrease in lesion size).
4. Safety assessment (no side effects).

H. Timeline

Patients receiving laser treatment were assessed every second, fourth, and sixth week. Haemangioma lesions were monitored by clinical examination every 2 months.

I. Procedure

Any cosmetics or makeup were removed, and the skin was cleaned. The area was anaesthetised by the application of

EMLA lotion (lidocaine 2.5% +prilocaine 2.5%) [ONLY MEDICAL; CAT No. R331/72394/PO01] for 20 minutes. The laser probe was held perpendicular to the lesion. The patient wore protective eye goggles [CE; DIR 8001100L4]. After the session, cool air was applied to the region. Each patient received a maximum of six sessions, delivered at two-week intervals. Following the procedure, all patients were advised to apply sunscreen (sun protection factor (30%)) during any periods of sun exposure exceeding 15 minutes.

The trial treatment was randomly assigned to two areas, such as the face, lip, or upper eyelid. The treated sites for each patient differed according to the location of their haemangioma. The outcome includes the skin texture, and the smoothness, colour, and the depth of lesions, and photographs of the patient's lesion (before and after). A computer histogram method was used to show the difference between the two photographs, before and after laser treatment.

The laser wavelength was selected as it is absorbed by the haemoglobin layer of the skin, because blood is the target, and the wavelength of the laser is absorbed by the haemoglobin layer as it acts as a chromophore (Patil & Dharmi, 2008). An anaesthetic cream was applied to the treated area, and after treatment the anaesthetic cream was removed. The laser was applied to the area to be treated. The session was painless because of the anaesthesia and the lack of side effects.

J. Clinical Examination

We conducted clinical examinations to inspect the site, colour, texture, area, consistency, and side effects, which were assessed and graded according to the NCI-CTCAE Version 4.0 (<http://ctep.cancer.gov/reporting/ctc.html>). The clinical examination was performed by us, with assistance from dermatologists.

K. Measurement of Quantitative Variables

For each patient, a digital image histogram [VELAS60B; Wuhan Gigaa Optronics Technology Co., Ltd.; SN: GA10-V307] was generated as a graph of the tonal distribution present (Figure 2). The pixels numbers were plotted for all tonal values, which allowed rapid evaluation of the tonal

distribution (Mohamad *et al.*, 2011). The very bright image histogram would be on the centre of the graph and right side (Freeman, 2011). The histogram plots represent specific brightness (horizontal axis) and the number of pixels (vertical axis) in the image and provide improvements in picture brightness and contrast (Evening, 2007).

L. Equipment and Parameters

The wavelength and pulse duration (ability and capacity of laser) of the laser (8 Watt) sessions delivered in the present study were modified according to the type of lesion, skin type, and patient's age.

M. The Histogram

The histogram method is a computerised method to show the difference between the two photos, before and after laser treatment, to show the difference between the two images of the same area of haemangioma. In image processing and histograms, the horizontal axis on the left-side indicates the dark or black regions, while the middle represents medium gray, and the horizontal axis on the right-side indicates the light and pure white areas. If the image is very dark, then the histogram would be in the left and centre, as shown in Figure 2.



Figure 2. The histogram

N. Trial Registration

The study underwent registration at clinicaltrials.gov NCT04065217 (Date: 21.08.2019), after initiation and completion of the study, due to the slow recording system of the institute, which led to a difference in dates between the study and the trial record.

O. Ethics

I confirm that I received written informed consent for the publication of this manuscript and that the research was conducted in accordance with the Helsinki Declaration 1975, (revised in 2000). Ethical Committee approval was granted by the Institute of Laser for Postgraduate Studies [No:1477, start date: 14/10/2018, registration and completion date: 21/08/2019].

P. Statistical Analysis

This was an open label trial; however, the statistician who performed the analyses was blinded to the treatment assignment. Also, an investigator blinded to treatment allocation performed the assessment of the end-points.

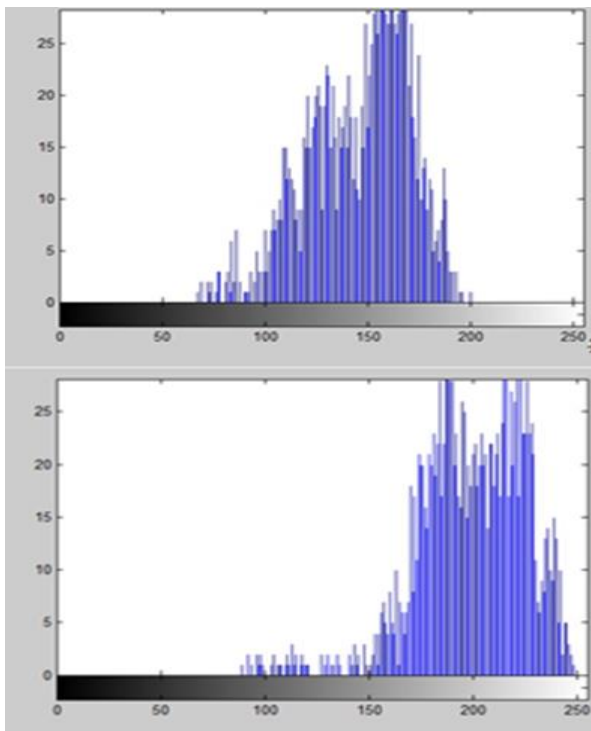
III. RESULTS AND DISCUSSION

The responses of all patients evaluated before and after laser treatment are presented as digital image histograms (Figure 3).

In Figure 3(a), the peak of the histogram before laser treatment is located in the gray level at 150 degrees, which means that the lesion is dark and the range of the histogram is from -60-200-, but in Figure 3b the peak of histogram after treatment is located between the end of the gray level and the beginning of the white level at 220 degrees and the range of the histogram is from 90-250. So this difference in value represents the response in the lesion after treatment because 220 is located in the bright level which means that there is a good response after treatment. This is demonstrated by the change in lesion colour from dark to bright.

After several sessions, the haemoglobin layer became fragmented under the skin, the elevation of the skin was gradually reduced, and the colour of the haemangioma was reduced from dark to light.

There were no side effects or complications recorded and there were no cases of lesion recurrence. Images were converted from spatial to frequency values using a process known as digitisation. This process involves conversion of the digital image to a set of numbers in the form of a two-dimensional matrix (M x N) with numbers ranging from 0 to 255 and 256 frequency values representing all gray-scale frequencies starting from bold black to bright white colour, in addition to the intensity of colour per pixel (per unit of the image). The histogram displays the image frequencies that vary from one image to another. In the present study, we showed the difference between the two images of the same area before and after laser treatment. In addition, the difference between the histogram of the image before and after laser treatment was used to produce a new histogram representing the difference between the two images and reflecting the results of the treatment. Changes in the skin colour intensity of the image before and after laser treatment represent the response to treatment (Figure 4).



Figures 4. A and B) depict the histograms before and after treatment, respectively; the X-axis represents the colour scale from 0- 255. The degree from 0-100 represents the black colour (dark level), 100-200 represents the gray colour (gray level) and from 200-250 represents the white colour (bright level).

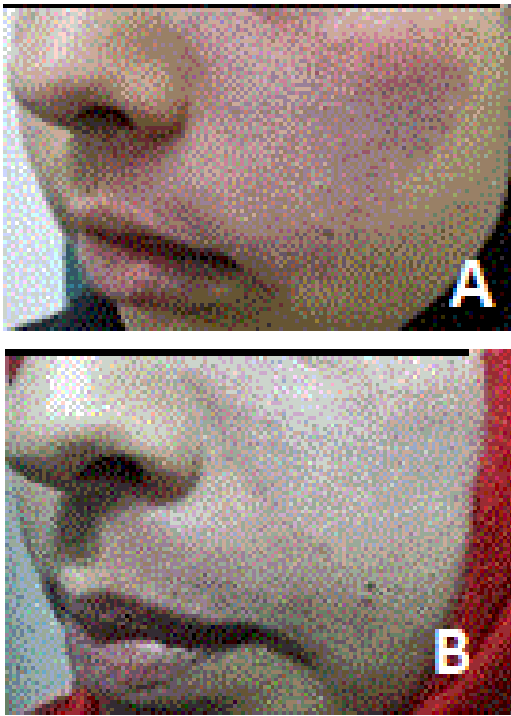


Figure 4. A) Before: Haemangiomas were elevated and dark red, and B) After: The skin texture had reduced elevation, was smoother, and the colour of the lesion had changed from dark red to light pink.

To the best of our knowledge, this is the first randomised trial of diode laser therapy in to treat haemangioma. Treatment for infantile haemangioma isn't not needed as this will fade over time. A child who has this lesion during infancy has had small seeing trace influence of the development by the age of ten (Genovese *et al.*, 2008). In small, superficial haemangiomas, a gel containing the drug beta beta-blocker drugs may be applied to the affected skin., This may cause disappearance of lesion lesions if also treated with an oral solution of propranolol, which usually need needs to be continued until about 1 year of age, with although there may be undesired undesirable adverse effects, include including high level of blood blood-sugar levels, slight low blood pressure, and wheezing (Genovese *et. al.*, 2008; Angiero *et al.*, 2008). As the A haemangioma is a bright red birthmark that shows up appears at birth or in during the first or second week of life and looks like a rubbery bump and is made up of extra additional blood vessels in the skin; commonly, the surgical lasers are commonly used for the treatment (Genovese *et al.*, 2008). The use of an endo lesion 980-nm diode laser for treatment of haemangioma in pediatric vascular or lympho- venous lesions has been reported (Angiero *et al.*, 2008), whereas in

other studies of infantile haemangiomas, the standard of care of management is has been to remove lesions at an early age for good involution process by propranolol. The efficacy of diode laser lasers efficacy for telangiectasias the management of telangiectasias has also been evaluated by Cerrati *et al.* (Cerrati *et al.*, 2014).

Infantile nasal haemangiomas comprise 15% of head and neck lesions, although lip haemangiomas are also common (Waner & Teresa, 2018). Clinical studies of soft-tissue wound healing following the application after diode laser of 980-nm diode laser treatment application have been reported (Romanos & Nentwig, 1999). In the haemangioma of the lip, the dehydration forced with by photocoagulation inducing induced by high-power diode lasers produced excellent results (Jasper *et al.*, 2015). The limitations of this the present study include the open label design, small number of less patients number, and short study time duration.

Other uses for this type of lasers have been suggested mentioned by (Mohammed & Mahmood, 2020). The laser we used was found as to be useful as a surgical tool. It is portable, easy to operate, and safe when recommended applications are adhered to, the accessory chosen is useful for interstitial application (Abbood *et al.*, 2015).

IV. CONCLUSION

It is necessary to develop improved treatments for face haemangiomas. The information from this randomised within-patient trial provides an introductory view of the use of diode lasers in haemangioma management and a basis for the design and estimations of new studies. Based on our results, a 980-nm diode laser is an effective and safe process for the relief of haemangiomas of the face.

A. Data Availability

Noor Taha Ismaeel Ali. (2019). The Effectiveness of Diode Laser 980-nm in Iraqi Face Haemangioma: Clinical study. Zenodo. <http://doi.org/10.5281/zenodo.3338657>

V. REFERENCES

- Abbood, AA, Hajim, KI & Araji, ZY 2015, 'An in vitro histological study of human skin wound soldering using 980 nm diode laser in continuous versus pulsed modes', *Iraqi J. Laser, Part B*, vol. 14, pp. 1-10.
- Angiero, F, Benedicenti, S, Benedicenti, A et al. 2008, 'Head and neck hemangiomas in paediatric patients treated with endolesional 980-nm diode laser', *Photomedicine and Laser Surgery*, vol. 27, no. 4, pp. 553-9.
- Angiero, F, Benedicenti, S, Romanos, GE et al. 2008, 'Treatment of hemangioma of the head and neck with diode laser and forced dehydration with induced photocoagulation', *Photomed Las Surg*, vol. 26, no. 2, pp. 113-8.
- Cerrati, EW, Teresa, MO, Chung, H et al. 2014, 'Diode laser for the treatment of telangiectasias following hemangioma involution', *Otolaryngology-Head and Neck Surgery*, vol. 152, no. 2, pp. 239-43.
- Evening, M 2007, 'Adobe Photoshop CS3 for photographers: a professional image editor's guide to the creative use of photoshop for the Macintosh and PC', 1st edn. Focal Press, Taylor & Francis Group 2007.
- Freeman, M 2011, 'The Digital SLR Handbook', Octopus Publishing Group; 3rd UK ed.2011.
- Genovese, WJ, dos Santos, MTBR, Faloppa, F et al. 2008, 'The use of surgical diode laser in oral hemangioma: a case report', *Photomedicine and Laser Surgery*, vol. 28, no. 1, pp. 147-51.
- Hamou, C, Diner, PA, Dalmonte, P et al. 2010, 'Nasal tip haemangiomas: Guidelines for an early surgical approach', *J Plas Recons Aesth Surg*, vol. 63, no. 6, pp. 934-9.
- Husain, Z & Alster, T 2016, 'The role of lasers and intense pulsed light technology in dermatology', *Clin Cosm Invest Derm*, vol. 9, no. 54, pp. 29-40.
- ISSVA Classification of Vascular Anomalies International Society for the Study of Vascular Anomalies, retrieved 11 August 2018.
- Jasper, J, Camilotti, RS, Pagnoncelli, RM et al. 2015, 'Treatment of lip hemangioma using forced dehydration with induced photocoagulation via diode laser: report of three cases', *Oral Surgery, Oral Medicine, Oral Pathology and Oral Radiology*, vol. 119, no. 3, pp. 89-94.
- Karnofsky, DA & Burchenal, JH 1949, 'The clinical evaluation of chemotherapeutic agents in cancer', New York: Columbia University Press, pp. 191-205.
- Mohamad, FS, Manaf, AA & Chuprat S, 2011, 'Histogram-based fruit ripeness identification using nearest-neighbour Distance', *Proceedings of The Third International Conference on Computer Engineering and Technology, (ICCET 2011)*; pp. 483-9.
- Mohammed, DN & Mahmood, AS 2020, 'Low Fistula in Ano Treatment using Diode Laser 980-nm', *Iraqi J. Laser*, vol. 19, no. 1, pp. 35-44.
- Patil, UA & Dhama, LD 2008, 'Overview of lasers', *Indian Journal of Plastic Surgery: official publication of the Association of Plastic Surgeons of India*, vol. 41(Suppl), pp. S101-S113.
- Romanos, G & Nentwig, GH 1999, 'Diode laser (980-nm) in oral and maxillofacial surgical procedures: clinical observations based on clinical applications', *Journal of Clinical Laser Medicine & Surgery*, vol. 17, no. 5, pp. 193-7.
- Ulrich, H, Bäuml, W, Hohenleutner, U et al. 2005, 'Neodymium-YAG laser for hemangiomas and vascular malformations – long term results', *J the German society Derma*, vol. 3, no. 6, pp. 436-40.
- Vechio, AD, Nakajima, E, Pinto, JrD et al. 2013, 'Rhabdomyomatous (mesenchymal) hamartoma presenting as hemangioma on the upper lip: A case report with Immunohistochemical analysis and treatment with high-power lasers', *Case Repor Dentis*, vol. 94, no. 3953, pp. 1-3.
- Waner, M & Teresa, MO 2018, 'Nasal and lip infantile hemangiomas', in: Perkins JA and Balakrishnan K (edt.s). *Evidence-Based Management of Head and Neck Vascular Anomalies*. Springer International Publishing AG, Springer Nature, USA, pp. 121-9.